

Review Article

Open Access

Ultrasound Guided Dextrose Prolotherapy for Persistent Coccygeal Pain: A Case Series and Review of Literature

Yin-Ting Chen^{1*}, Chelsea Brundage², Sarah C Griffin³, Ian C Murphy³ and Arthur Jason De Luigi⁴¹Physical Medicine and Rehabilitation Service, Department of Orthopaedic and Rehabilitation, Ft. Belvoir Community Hospital, Ft. Belvoir, Virginia, USA²Physical Medicine and Rehabilitation Service, Department of Orthopaedic and Rehabilitation, Womack Army Medical Center, Fayetteville, NC, USA³Physical Medicine & Rehabilitation Service, Department of Orthopedic & Rehabilitation, Walter Reed National Military Medical Center, Bethesda, Maryland, USA⁴Director of Sports Medicine, Department of Rehabilitation Medicine, MedStar National Rehabilitation Hospital/Georgetown University Hospital, Washington, DC, USA**Abstract**

Coccydynia is a common condition that has been difficult to treat effectively with conventional pain relief methods. There has been previous research demonstrating safety and efficacy of prolotherapy to treat coccydynia. Many of the original descriptions were performed utilizing landmark or palpation guided techniques. However, there is evidence that imaging guidance improves accuracy of injections for axial and appendicular injections. We describe the use of ultrasound guidance for prolotherapy to accurately guide treatment into the coccyx in three patients leading to pain relief, improvement of motor function, and decrease in analgesic usage after treatment.

Keywords: Coccydynia; Prolotherapy; Sacrococcygeal joint**Introduction**

Coccydynia, or pain in the coccyx, is marked by significant pain in and around the coccyx that does not radiate, and is made worse by sitting or by standing up from the sitting position [1]. It may impair the patient's ability to perform activities of daily living (ADLs) such as sitting, standing, walking, and defecation. Coccydynia is most commonly caused by direct trauma to the coccyx such as falling. The trauma leads to inflammation and edema with possible subluxation or abnormal hypermobility of the coccyx [2]. The differential diagnosis of coccygeal pain includes other conditions such as bursitis of the adventitia at the coccygeal tip, traumatic arthritis of the sacrococcygeal joint, non-united fractures, irregular tumors or cysts on the coccyx, lesions to the surrounding areas, arachnoiditis, or precoccygeal calcific tendinitis [3]. Careful workup is needed to rule out these underlying conditions prior to treatment for pain. Various abnormal radiographic findings associated with coccydynia have been described and may be detectable within three months from onset of pain to, such as coccygeal retroversion with spicules, scoliotic deformity, or coccygeal anteversion, anterior or posterior subluxation, hypermobility. However, up to 30% of cases may have no identifiable radiographic abnormalities [4-6].

Even when the etiology of coccydynia can be determined, current treatments for the condition tend to be either ineffective or provide incomplete relief. Conservative therapies for coccydynia such as heat, ice, topical anesthetic, and intrarectal manual manipulation have been shown to have limited efficacy. Physiotherapy has been shown to have a 16% cure rate [7]. Maigne and Chatterlier [1] reported the six-month success rate for initial treatment with levator ani massage to be 29.2%, levator ani stretching to be 32%, and sacrococcygeal joint mobilization to be 16% for an overall success rate of 25.7% [1]. Local corticosteroid injection alone or with manipulation has been shown to have success rate of 60% and 85%, respectively, but nearly one-third of the patients experience relapse of the symptoms within one year [7]. While coccygectomy is an effective treatment for refractory cases, its invasive nature and potential postoperative complications such as infection and rectal drainage lead clinicians to continue to search for alternative effective conservative treatments [4].

Recently, prolotherapy has emerged as a promising treatment for

recalcitrant coccydynia. Khan and colleagues demonstrated a significant decrease in self-reported coccyx pain via the visual analog score (VAS) in patients treated with prolotherapy [8]. While encouraging, this research examined injections guided by palpation alone which were performed without direct imaging. Injections were targeted to superficial areas experiencing the most intense pain. Image guidance improves the accuracy of injections through direct visualization of the needle into the target. There are multiple options for image guidance during interventional procedures including ultrasound, fluoroscopy, and computerized tomography (CT). Ultrasound has the advantage over other imaging modalities in that it spares the patient radiation exposure, is cost effective and portable. The use of ultrasound to facilitate the identification of musculoskeletal structures and thereby improve interventional accuracy is well documented, and is rapidly becoming adapted in multiple disciplines to improve diagnostic and therapeutic safety [9,10]. We present our experience with three patients who underwent ultrasound-guided prolotherapy injections for treatment of persistent coccydynia.

Procedure

The patient is placed in prone position with the coccyx region exposed to allow examination. A GE Logiq E ultrasound machine (GE Healthcare, United Kingdom) equipped with small profile 4-10 MHz transducer ("hockey stick probe") is used. The transducer is placed in long axis over the coccyx on the point of maximum tenderness, which usually involves either the sacrococcygeal (SCo) or the Co1-Co2 joint (Figure 1). A diagnostic ultrasound survey is conducted over the area to evaluate for any anatomical abnormalities. Doppler ultrasound is

***Corresponding author:** Yin-Ting Chen, Ft. Belvoir Community Hospital, 9300 DeWitt Loop, Ft. Belvoir, VA 22060, USA, Tel: 571-231-3224; E-mail: ychent@gmail.com

Received September 27, 2013; **Accepted** October 25, 2013; **Published** October 28, 2013

Citation: Chen YT, Brundage C, Griffin SC, Murphy IC, Luigi AJD (2013) Ultrasound Guided Dextrose Prolotherapy for Persistent Coccygeal Pain: A Case Series and Review of Literature. *Altern Integ Med* 2: 142. doi:[10.4172/2327-5162.1000142](http://dx.doi.org/10.4172/2327-5162.1000142)

Copyright: © 2013 Chen YT, et al. This is an open-access article distributed under the terms of the Creative Commons Attribution License, which permits unrestricted use, distribution, and reproduction in any medium, provided the original author and source are credited.

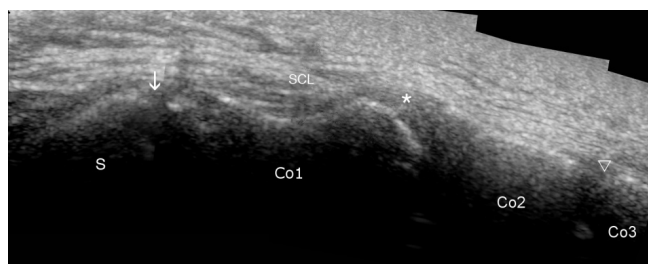


Figure 1: Composite image of the sacrum and coccyx in long-axis. The sacrum (S) is proximal to Co1, divided by the sacrococcygeal joint (arrow). The Co1-Co2 joint (asterisk) and the Co2-3 joint (triangle) divide the corresponding segments. The sacrococcygeal ligament (SCL) can be observed overlying the entire length of the coccyx.

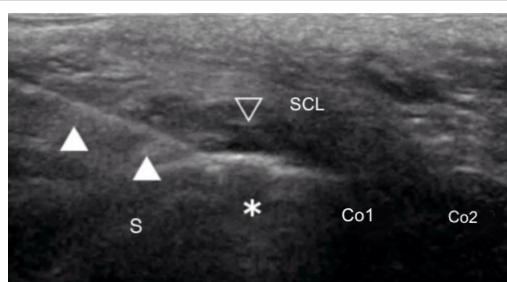


Figure 2a: Injection of the prolotherapy. The sacrococcygeal joint (asterisk) is centered in the field in longitudinal axis, dividing the sacrum (S) and the coccyx (Co1, Co2). The needle (closed triangle) is guided to the joint through a in-plane, cephalad-to-caudal approach, entering the sacrococcygeal joint just deep to the sacrococcygeal ligament (SCL). The injectate is seen as a hypoechoic collection (Opened triangle), lifting off the sacrococcygeal ligament. B)

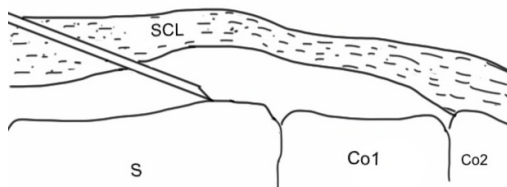


Figure 2b: Diagrammatic presentation of figure 2a.

used to detect any abnormal neovascularization in the region. Prior to injection, the area is prepared with sterile techniques, then under ultrasound guidance, a 25-gauge needle is inserted into the targeted joint through a cephalad-to-caudal approach in-plane of the ultrasound image. Fenestration is performed by passing the needle through the posterior sacrococcygeal ligament multiple times, and then a 3 mL injectate composed of 1.5 mL of 50% dextrose solution and 1.5 mL of 1% lidocaine is injected deep to the ligament at the point of maximum tenderness (Figure 2a and 2b). Following the procedure, the patient is instructed to rest, avoid using NSAIDs and is prescribed acetaminophen or tramadol as needed for pain control for the first week. Patient is then instructed to gradually return to regular activity thereafter. Follow up is scheduled after 3 weeks with additional follow up as clinically indicated.

Case 1

The patient was a 62 year-old male with two months of coccyx pain as a result of falling from standing height and landing on his coccyx. At initial examination he rated his pain at a visual analog (VAS) of

7-8/10. There was no evidence of fracture or dislocation of the coccyx on radiograph. The pain was exacerbated by sitting, which interfered with his occupation as an office manager as he could only tolerate 1-2 hours of sitting at a time. The patient had tried standard treatments to include the use of donut cushions and manual manipulation therapy, without pain improvement. The patient was taking oxycodone 10 mg three times daily and acetaminophen-codeine as needed without satisfactory pain relief.

On initial presentation, inspection of the posterior lumbar, sacral, gluteal and coccygeal region did not reveal any ecchymosis, hematoma, lesions or gross deformities. The coccyx segments were mobile on palpation though movement caused pain. There was no tenderness in the posterior sacroiliac spine (PSIS) and ischial tuberosities. The examination was otherwise unremarkable.

Ultrasound examination of the painful region was notable for positive sonopalpation, reproducing his pain upon mobilization of the SCo and Co1-Co2 joints by the ultrasound transducer. After counseling and consent, the patient underwent ultrasound-guided coccyx prolotherapy delivered to the SC joint and the Co1-Co2 joint. At the six week follow up visit, the patient reported 0/10 pain while standing and pain-free sitting for up to 3 hours. The patient was satisfied with the treatment and able to return to full-time employment.

Patient 2

The patient was a 45 year-old female with chronic low back and coccyx pain since falling down a flight of stairs five years prior. Her pain was described as continuous, rated at 6/10 on VAS, and exacerbated by standing, back extension, prolonged sitting and direct palpation of her coccyx region. The patient had previously tried different medications to include acetaminophen, ibuprofen and meloxicam for pain with minimal improvement.

Examination indicated tenderness upon palpation of the lumbar paraspinal muscles, back extension limited by pain, negative straight leg test, negative Gillet test, negative Patrick/Faber tests, and negative Gaenslen's sign. Palpation of sacroiliac joints and coccyx did not elicit any discomfort. The patient had normal sensation to light touch and strength in all muscle groups of the bilateral lower extremities. Her reflexes were normal and symmetric. Lumbar spine x-rays demonstrated bilateral pars interarticularis defects and facet arthropathy at L5/S1.

The ultrasound examination of her lower coccyx demonstrated normal anatomical landmarks. After counseling, the patient elected to undergo ultrasound-guidance prolotherapy of the sacrococcygeal junction. At four week follow up the patient reported improvement of her pain to 2/10. She also reported being able to sit for longer periods of time as well as ambulate comfortably. At 12 weeks follow, her pain remained below her initial report and she reported improvements her overall functional status.

Patient 3

The patient was a 61 year-old female with a three year history of back pain, bilateral leg pain, hip pain and coccyx pain that started acutely one night with no history of trauma. The patient's pain ranged from 8-10/10 and was initially associated with incontinence, left lower extremity pain, and paresthesias of the left medial thigh down to the heel. Initial workup ruled out emergent neurological impingement. She previously received two rounds of lumbar epidural steroid injections without improvement, as well as trials of oxycodone-acetaminophen, baclofen, nortriptyline and cyclobenzaprine.

Upon examination the patient demonstrated tenderness to palpation over her bilateral hips, mid gluteus region, posterior superior iliac spines, sacroiliac joints, and piriformis muscles. She showed moderate tenderness to palpation of her coccyx. Back flexion and extension were normal in range and straight leg test was negative bilaterally. Provocative tests for sacroiliac joint pathology were normal. Lower extremity neuromuscular exam was normal.

Ultrasound examination of her coccyx did not reveal any notable ligamentous or osseous abnormalities, but sonopalpation reproduce the pain. After counseling and consent, the patient underwent ultrasound-guided prolotherapy targeting the sacrococcygeal junction. At four week follow up, the patient reported a decrease in her coccygeal pain from an 8/10 to a 5/10. At 10 weeks follow up, she reported near complete resolution of her coccygeal pain and had returned to normal function.

Discussion

This paper presents three cases of successful, sustained relief of significant coccyx pain using ultrasound-guided prolotherapy. All three patients reported improvements in pain scores, mobility, functional status, and decreased analgesic usage following treatment. There were no complications noted during or in the weeks following the procedures, and the patients did not require additional injections during follow-up appointments.

This case series expands upon previous work demonstrating the efficacy of prolotherapy for coccydynia [8]. Prolotherapy is based on the theory that the injection of growth factors or growth factor production stimulants into a region will promote growth and repair of normal cells and tissue [8], and potentially offers a minimally invasive treatment strategy for pain syndromes. Dextrose, a common choice for prolotherapy, has been shown to elicit growth factor production when the body is exposed to the substance in supraphysiologic concentration [8], leading to damaged tissue repair and pain reduction [11,12]. The current literature on prolotherapy is confounded by limited methodological quality. Yet a recent met-analysis by Staal and colleagues concluded that while there's insufficient evidence for or against the use of any type of injection therapy, however, "it cannot be ruled out that specific subgroups of patients may respond to a specific type of injection therapy" [13]. Ultrasound-guided prolotherapy may represent a safe and efficacious alternative treatment to surgical intervention for coccygeal pain when conservative treatment fails.

The addition of ultrasound guidance refines prolotherapy injection procedures. Ultrasound provides high resolution images of soft tissues, enables dynamic evaluation of structures during examination, allows for the differentiation of tissues, and can discern tissue pathology based on sonographic characteristics. Ultrasound is also non-invasive and has next to no contraindications for usage. It is affordable, modular, portable, and can readily be deployed into a clinical practice of any size. These benefits improve the safety of office-based invasive procedures by providing direct, real-time visualization, thereby allowing providers to avoid injuring vital structures while they gain access to the target structures [14]. Moreover, the improved accuracy of ultrasound-guided injection compared to unguided injection is well established in the literature [15-20]. The use of ultrasound allows for direct placement of needles for prolotherapy under direct visualization, potentially limiting complications and improving the accuracy of injectate delivery. Research has demonstrated that prolotherapy under ultrasound guidance produces positive outcome in Achilles tendinopathy [21,22]. In our case series, the use of ultrasound allowed us to visually confirm the site of pathology, define the anatomy, and deliver the prolotherapy

accurately.

Ganglion impar block is frequently cited as a minimally invasive procedure for management of coccydynia and chronic perineal pain. The procedure has a high success rate and shows significant reduction in self-reported pain scores across small sample sizes [23,24]. Nonetheless, the procedure relies on fluoroscopic identification of the relevant structures and requires technically-demanding transsacrococcygeal needle placement to properly accomplish the ganglion block [23]. Ultrasound guidance allows for more precise visualization of anatomical structures and allows the detection and avoidance of any local anatomical abnormalities such as abscesses or ossified tissue. The risk of rectal injury from transsacrococcygeal or transintercoccygeal joint injection is minimal as long as proper needle technique is followed. The visualization of the needle tip should be maintained while advancing the needle toward the target. A shallow angle of needle approach required to access the relative superficial coccyx structures also reduces the likelihood of penetrating the joints to injure the rectum. This precision minimizes the risk of accidental rectal injury, a potential complication in both blind and fluoroscopic guided techniques. Thus ultrasound guidance may improve the safety of established procedures to treat coccydynia and chronic perineal pain.

While the results of this case series are promising, these findings need to be confirmed by larger clinical trials with longer follow-up period to determine the efficacy, duration of effects, and potential complications of ultrasound-guided prolotherapy. Furthermore, additional research is necessary to determine the optimal procedure for this therapy in addition to the clinical characteristics that identify patients who would maximally benefit from the treatment. Finally, additional studies should investigate the effectiveness of ultrasound-guided prolotherapy in the treatment of other chronic pain conditions besides coccydynia.

Conclusion

Prolotherapy shows potential as an effective and minimally invasive treatment of coccydynia in patients who do not respond to standard conservative treatments. The use of ultrasound guidance offers additional accuracy and safety. Further research with clinical trials is necessary to substantiate these results as well as determine the standard procedure, duration of effects, potential complications, and ideal patients for this treatment.

References

1. Maigne JY, Chatellier G (2001) Comparison of three manual coccydynia treatments: a pilot study. *Spine (Phila Pa 1976)* 26: E479-483.
2. Maigne JY, Tamalet B (1996) Standardized radiologic protocol for the study of common coccygodynia and characteristics of the lesions observed in the sitting position. Clinical elements differentiating luxation, hypermobility, and normal mobility. *Spine (Phila Pa 1976)* 21: 2588-2593.
3. Moon SG, Kim NR, Choi JW, Yi JG (2012) Acute coccydynia related to precoccygeal calcific tendinitis. *Skeletal Radiol* 41: 473-476.
4. Fogel GR, Cunningham PY 3rd, Esses SI (2004) Coccygodynia: evaluation and management. *J Am Acad Orthop Surg* 12: 49-54.
5. Maigne JY, Doursounian L, Chatellier G (2000) Causes and mechanisms of common coccydynia: role of body mass index and coccygeal trauma. *Spine (Phila Pa 1976)* 25: 3072-3079.
6. Maigne JY, Pigeau I, Roger B (2012) Magnetic resonance imaging findings in the painful adult coccyx. *Eur Spine J* 21: 2097-2104.
7. Wray CC, Easom S, Hoskinson J (1991) Coccydynia. Aetiology and treatment. *J Bone Joint Surg Br* 73: 335-338.
8. Khan SA, Kumar A, Varshney MK, Tripathi V, Yadav CS (2008) Dextrose

- prolotherapy for recalcitrant coccygodynia. *J Orthop Surg* 16: 27-29.
9. Davidson J, Jayaraman S (2011) Guided interventions in musculoskeletal ultrasound: what's the evidence? *Clin Radiol* 66: 140-152.
 10. Fullerton BD, Reeves KD (2010) Ultrasonography in regenerative injection (prolotherapy) using dextrose, platelet-rich plasma, and other injectants. *Phys Med Rehabil Clin N Am* 21: 585-605.
 11. Topol GA, Reeves KD, Hassanein KM (2005) Efficacy of dextrose prolotherapy in elite male kicking-sport athletes with chronic groin pain. *Arch Phys Med Rehabil* 86: 697-702.
 12. Fullerton BD (2008) High-resolution ultrasound and magnetic resonance imaging to document tissue repair after prolotherapy: a report of 3 cases. *Arch Phys Med Rehabil* 89: 377-385.
 13. Staal JB, de Bie R, de Vet HC, Hildebrandt J, Nelemans P (2008) Injection therapy for subacute and chronic low-back pain. *Cochrane Database Syst Rev* 16: CD001824.
 14. Smith J, Finnoff JT (2009) Diagnostic and interventional musculoskeletal ultrasound: part 1. Fundamentals. *PM R* 1: 64-75.
 15. Finnoff JT, Nutz DJ, Henning PT, Hollman JH, Smith J (2010) Accuracy of ultrasound-guided versus unguided pes anserinus bursa injections. *PM R* 2: 732-739.
 16. Wisniewski SJ, Smith J, Patterson DG, Carmichael SW, Pawlina W (2010) Ultrasound-guided versus nonguided tibiotalar joint and sinus tarsi injections: a cadaveric study. *PM R* 2: 277-281.
 17. Muir JJ, Curtiss HM, Hollman J, Smith J, Finnoff JT (2011) The accuracy of ultrasound-guided and palpation-guided peroneal tendon sheath injections. *Am J Phys Med Rehabil* 90: 564-571.
 18. Curtiss HM, Finnoff JT, Peck E, Hollman J, Muir J, et al. (2011) Accuracy of ultrasound-guided and palpation-guided knee injections by an experienced and less-experienced injector using a superolateral approach: a cadaveric study. *PM R* 3: 507-515.
 19. Lee DH, Han SB, Park JW, Lee SH, Kim KW, et al. (2011) Sonographically guided tendon sheath injections are more accurate than blind injections: implications for trigger finger treatment. *J Ultrasound Med* 30: 197-203.
 20. Peck E, Lai JK, Pawlina W, Smith J (2010) Accuracy of ultrasound-guided versus palpation-guided acromioclavicular joint injections: a cadaveric study. *PM R* 2: 817-821.
 21. Maxwell NJ, Ryan MB, Taunton JE, Gillies JH, Wong AD (2007) Sonographically guided intratendinous injection of hyperosmolar dextrose to treat chronic tendinosis of the Achilles tendon: a pilot study. *AJR Am J Roentgenol* 189: W215-220.
 22. Ryan M, Wong A, Taunton J (2010) Favorable outcomes after sonographically guided intratendinous injection of hyperosmolar dextrose for chronic insertional and midportion achilles tendinosis. *AJR Am J Roentgenol* 194: 1047-1053.
 23. Toshniwal GR, Dureja GP, Prashanth SM (2007) Transsacroccocygeal approach to ganglion impar block for management of chronic perineal pain: a prospective observational study. *Pain Physician* 10: 661-666.
 24. Demircay E, Kabatas S, Cansever T, Yilmaz C, Tuncay C, et al. (2010) Radiofrequency thermocoagulation of ganglion impar in the management of coccydynia: preliminary results. *Turk Neurosurg* 20: 328-333.

Citation: Chen YT, Brundage C, Griffin SC, Murphy IC, Luigi AJD (2013) Ultrasound Guided Dextrose Prolotherapy for Persistent Coccygeal Pain: A Case Series and Review of Literature. *Altern Integ Med* 2: 142. doi:[10.4172/2327-5162.1000142](https://doi.org/10.4172/2327-5162.1000142)

Submit your next manuscript and get advantages of OMICS Group submissions

Unique features:

- User friendly/feasible website-translation of your paper to 50 world's leading languages
- Audio Version of published paper
- Digital articles to share and explore

Special features:

- 250 Open Access Journals
- 20,000 editorial team
- 21 days rapid review process
- Quality and quick editorial, review and publication processing
- Indexing at PubMed (partial), Scopus, EBSCO, Index Copernicus and Google Scholar etc
- Sharing Option: Social Networking Enabled
- Authors, Reviewers and Editors rewarded with online Scientific Credits
- Better discount for your subsequent articles

Submit your manuscript at: <http://www.omicsonline.org/submission>

